Diffuse Shedding, Immune-Mediated Hair Loss, Cicatricial Alopecia and Scalp Disease

HLI / IIIOHR Advanced Trichology Academy — Postgraduate Manual Series

This volume develops physician-level competence in non-patterned hair loss, inflammatory scalp disease, and cicatricial alopecia. Written as both a teaching manual and a source text for structured online learning, Volume 3 trains doctors to recognise when diffuse shedding is benign and self-limited, when patchy loss reflects immune-mediated disease, when breakage is being mistaken for true alopecia, and when scalp symptoms indicate an urgent cicatricial process requiring immediate intervention.

ADVANCED TRICHOLOGY ACADEMY | POSTGRADUATE SERIES | VOLUME 3

Volume Overview

Volume 3 moves beyond patterned hair loss into the broader field of clinical hair and scalp medicine. The central educational aim is to train doctors to recognise when diffuse shedding is benign and self-limited, when patchy loss reflects immune-mediated disease, when breakage is being mistaken for true alopecia, and when scalp symptoms and permanent loss indicate an urgent cicatricial process. The volume also strengthens competence in common inflammatory and infectious scalp disease, which frequently coexists with alopecia or confounds diagnosis.

> **Educational focus:** Diagnostic reasoning, disease classification, trichoscopy patterns, biopsy logic, treatment prioritisation, and longitudinal management in disorders where delayed recognition can permanently alter outcome.

Modules Included

01

Module 10

Telogen Effluvium and Diffuse Shedding Disorders

02

Module 11

Alopecia Areata and Immune-Mediated Hair Loss

03

Module 12

Hair Shaft Disorders and Breakage Syndromes

04

Module 13

Principles of Cicatricial Alopecia

05

Module 14

Lymphocytic Cicatricial Alopecias

06

Module 15

Neutrophilic and Mixed Cicatricial Alopecias

07

Module 16

Inflammatory and Infectious Scalp Disorders

MODULE 10

Telogen Effluvium and Diffuse Shedding Disorders

Diffuse shedding is one of the most common reasons patients seek hair consultation. The clinician's task is not simply to label the condition as telogen effluvium, but to decide whether shedding is acute or chronic, whether a trigger is identifiable, whether patterned loss is present in the background, and whether the amount of loss is consistent with the history, examination, and trichoscopy findings.

Learning Objectives

- Differentiate acute telogen effluvium, chronic telogen effluvium, anagen shedding, and diffuse patterned loss.
- Construct a trigger timeline using illness, surgery, childbirth, stress, nutritional change, and medication exposure.
- Recognise the overlap between telogen effluvium and androgenetic alopecia in both male and female patients.
- Use trichoscopy and laboratory testing to avoid overdiagnosis and underdiagnosis.

10.1 — Pathophysiology of Shedding

Core Mechanism

Telogen effluvium reflects a shift in follicular cycling rather than follicular destruction. A physiologic or systemic stress pushes a larger-than-normal proportion of follicles out of anagen and into telogen, leading to increased shedding two to four months later in classic acute presentations.

The concept is simple, but real cases are more complex: repeated stressors, inflammatory disease, endocrine disruption, metabolic disturbance, medication effects, and background patterned miniaturisation can all influence the final presentation.

Clinical Reasoning

A patient does not present at the moment of follicular shift; they usually present weeks to months later, when shedding becomes visible. The timeline is therefore central to diagnosis. Reconstructing the 3–6 month window prior to symptomatic shedding is the single most productive clinical maneuver in diffuse hair loss evaluation.

Understanding that telogen effluvium is a cycling phenomenon — not a structural disease — shapes both the diagnostic workup and the counseling approach. It also clarifies why recovery, when the trigger is removed, may itself be delayed by weeks to months.

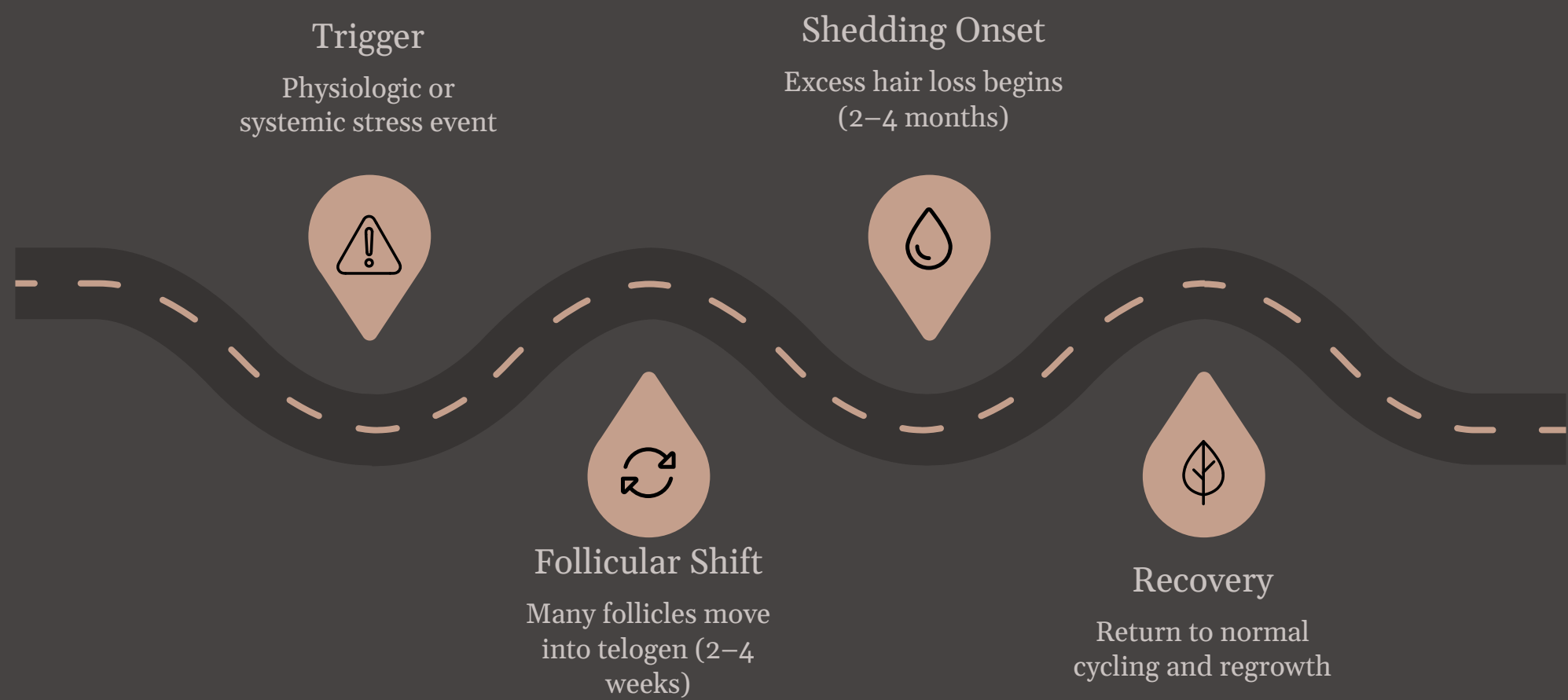

The above timeline illustrates the classic latency pattern in acute TE — a feature that frequently misleads patients and clinicians who cannot identify a proximate event. Mapping back from the onset of shedding to the trigger window is the most clinically efficient diagnostic strategy.

10.2 — Acute Telogen Effluvium

Acute telogen effluvium typically follows a recognisable event such as febrile illness, major psychological stress, surgery, rapid weight loss, postpartum transition, severe dietary restriction, or medication change. Patients describe increased daily hair fall, hair on pillows and in the shower, and reduced ponytail density or overall volume. Examination may show global reduction in density, but complete bald areas are absent and the scalp is usually non-inflamed.

Common Triggering Events

Physiologic Stress

Postpartum transition, febrile illness, major surgery, rapid or extreme weight loss

Psychological Stress

Severe acute psychological trauma, chronic high-burden stress with identifiable onset

Nutritional Deprivation

Crash dieting, bariatric surgery, severe dietary restriction, protein-energy malnutrition

Medication Exposure

New systemic medication, anticoagulants, retinoids, hormonal changes, chemotherapy agents

Clinical examination in acute TE generally reveals diffuse reduction in density without focal patches, a non-inflamed scalp, and preserved follicular openings on trichoscopy. The pull test may be positive. When findings deviate from this picture — particularly when trichoscopy reveals yellow dots, black dots, or perifollicular changes — the differential must be expanded.

10.3 — Chronic Telogen Effluvium & Differential Diagnosis

Chronic telogen effluvium is best understood as persistent excessive shedding with relatively preserved density, often in women, in whom repeated triggers, low iron stores, thyroid disturbance, metabolic stress, chronic inflammation, or anxiety around recurrent shedding may contribute. Chronic TE is frequently overused as a label. A doctor-level assessment asks whether chronic shedding is actually chronic TE, diffuse female pattern hair loss, early inflammatory disease, or a mixed picture.

Differential Diagnosis of Diffuse Shedding

Diffuse Androgenetic / FPHL

Miniaturisation on trichoscopy, accentuated frontal or crown loss, variable shedding complaint

Alopecia Areata Incognita

Diffuse presentation without discrete patches; yellow dots and black dots on trichoscopy are key

Anagen Effluvium

Chemotherapy, toxin, or systemic disease causing anagen-phase shedding, typically rapid onset

Thyroid Disease

Both hypothyroidism and hyperthyroidism can produce diffuse shedding; TSH and free T4 required

Iron Deficiency

With or without frank anaemia; serum ferritin is the most sensitive marker in this context

Inflammatory Scalp Disease

Seborrhoeic dermatitis, psoriasis, or early cicatricial disease may each generate diffuse shedding

Red Flags: Patchy loss, visible inflammation, scalp pain, pustules, scarring, eyebrow loss, significant body-hair change, or severe miniaturisation on trichoscopy should push the clinician beyond a simple TE diagnosis.

10.4 — Clinical Assessment Framework & Management

Clinical Assessment Framework

1. Establish onset, peak, and current severity of shedding
2. Map the timeline back 3–6 months for systemic triggers
3. Ask about illness, surgery, postpartum status, crash dieting, medications, thyroid symptoms, and menstrual change
4. Assess underlying patterned loss through frontal, midline, and crown density plus miniaturisation patterns
5. Order targeted laboratory testing rather than indiscriminate panels

Management Principles

Management begins with correcting the cause where possible, addressing nutritional or endocrine contributors, explaining the cycling biology clearly, and setting expectations regarding delayed recovery.

In pure acute TE, reassurance and trigger correction may be sufficient. In chronic shedding or TE overlapping with patterned loss, treatment may include management of the background AGA/FPHL as well as the shedding trigger.

LMS Mapping Note: The online lesson for Module 10 should include a timeline-based interactive case where the learner identifies the trigger window and selects the most appropriate investigations.

MODULE 11

Alopecia Areata and Immune-Mediated Hair Loss

Alopecia areata is an immune-mediated disease with a wide clinical spectrum ranging from small discrete patches to total scalp or body-hair loss. Although many patients present with classic sharply demarcated patches, the physician must also recognise ophiasis, diffuse forms, eyebrow and eyelash involvement, and presentations that mimic telogen effluvium or patterned loss.

Learning Objectives

- Recognise major phenotypes of alopecia areata and understand their prognostic implications.
- Use trichoscopy to support diagnosis and monitor disease activity.
- Differentiate alopecia areata from tinea capitis, traction alopecia, trichotillomania, and cicatricial disease.
- Build a practical treatment framework from local disease through extensive disease.

11.1 — Pathogenesis of Alopecia Areata

Immune Privilege Collapse

Alopecia areata is associated with collapse of normal follicular immune privilege and targeted inflammatory attack on the hair bulb. Under physiologic conditions, the hair follicle maintains a relative state of immune privilege partly mediated by local immunosuppressive mechanisms. In alopecia areata, this privilege is lost, exposing follicular antigens to cytotoxic T-cell recognition.

Genetic predisposition, autoimmunity, and environmental triggers interact to produce disease. The modern physician should understand that AA is not only a cosmetic condition; it can be chronic, relapsing, psychologically burdensome, and sometimes associated with other autoimmune tendencies including thyroid disease, vitiligo, and atopic disorders.

Key Pathogenic Concepts

- Loss of follicular immune privilege at the hair bulb
- CD8+ T-cell–mediated attack on anagen follicles
- JAK-STAT signaling pathway involvement
- Genetic susceptibility loci including HLA associations
- Environmental and infectious trigger interaction
- Association with autoimmune comorbidities
- Psychoneuroimmune contributions in some patients

11.2 — Clinical Phenotypes of Alopecia Areata

Patchy AA

Classic discrete, sharply demarcated, smooth patches; most common presentation; variable regrowth potential

Ophiasis Pattern

Band-like loss along the occipital and temporal margins; carries worse prognosis than patchy disease

Alopecia Totalis

Complete or near-complete scalp hair loss; often requires systemic treatment; chronic relapsing course

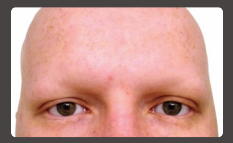

Alopecia Universalis

Total loss of scalp and body hair including eyebrows and eyelashes; most severe phenotype

Additional phenotypes include the sisaipho pattern (inverse ophiasis with retention of marginal hair), diffuse alopecia areata, and alopecia areata incognita — a diffuse form without discrete patches that can closely mimic telogen effluvium or female pattern hair loss. Isolated eyebrow, eyelash, beard, and body-hair involvement are also recognised phenotypic variants.

11.3 — Trichoscopy in Alopecia Areata

Trichoscopy is a critical tool in diagnosing and monitoring alopecia areata, particularly when the presentation is atypical or diffuse. The combination and prominence of trichoscopic features varies by disease activity, chronicity, and patient phenotype.

Yellow Dots

Follicular infundibula filled with sebum and keratinous material; marker of follicular dropout and disease activity

Black Dots

Fractured hairs retained within follicular openings; indicate active destruction of emerging anagen hairs

Exclamation-Mark Hairs

Tapered proximal shaft with normal distal diameter; highly specific for active AA; reflect proximal dystrophy

Short Vellus Regrowing Hairs

Fine upright regrowing hairs indicate transition back toward anagen; favorable prognostic sign

Broken Hairs

Variable-length broken shafts; may appear in active disease at patch margins

Clinical Reasoning: If the history suggests sudden diffuse shedding but trichoscopy shows numerous yellow dots, black dots, or tapered broken hairs, consider alopecia areata incognita before labelling the case as telogen effluvium.

11.4 — Differential Diagnosis of Alopecia Areata

Key Differentials

Tinea Capitis

Scale, broken hairs, adenopathy; especially in children; mycology required

Trichotillomania

Irregular patches, varied hair lengths, coiled hairs, absence of true follicular signs

Traction Alopecia

Distribution correlates with styling tension; marginal pattern; early reversibility

Secondary Syphilis

"Moth-eaten" pattern; systemic context; serology required

Early Scarring Alopecia

Loss of follicular openings, perifollicular inflammation; biopsy may be decisive

Treatment Framework Overview

Management is guided by severity, distribution, chronicity, patient age, associated comorbidity, and psychosocial impact. Limited patch disease may respond to topical or intralesional strategies, whereas extensive disease may require systemic therapy, specialist co-management, or newer immune-modulating approaches.

Even when discussing newer options, the clinician should frame treatment around risk, likelihood of response, chronic-relapsing behavior, and the importance of shared decision-making.

Red Flags: Rapidly progressive extensive loss, nail change, eyebrow and eyelash involvement, paediatric progression, or severe psychological distress justify early escalation and closer follow-up.

MODULE 12

Hair Shaft Disorders and Breakage Syndromes

Not all apparent hair loss is true follicular alopecia. Breakage may reduce hair length, volume, and cosmetic density while follicles remain intact. Doctors who do not actively separate breakage from shedding may overinvestigate patients or miss the real cause in grooming, chemical injury, hair shaft fragility, traction, or compulsive manipulation.

12.1 — Core Distinction: Breakage vs. Shedding

Shedding Disorders	Breakage Disorders
Patient loses whole club hairs from the follicle. Roots visible on shed hairs. Scalp density may be globally reduced. Trichoscopy shows cycling abnormalities.	Shorter fractured hairs accumulate. Length is reduced. Distal density is poor. Complaint is "thinning" despite preserved scalp density. No club roots on shed hairs.

History and close examination are decisive in separating these categories. The complaint of thinning hair in the context of preserved follicular density on trichoscopy should immediately prompt evaluation of shaft integrity, grooming habits, and chemical history.

12.2–12.4 — Clinical Categories, Trichoscopy & Management

Clinical Categories of Breakage

Congenital Shaft Abnormalities

Genetic fragility syndromes including monilethrix, trichorrhexis nodosa, pili torti, and Netherton syndrome. Morphologic shaft diagnosis on trichoscopy or light microscopy.

Acquired Weathering

Heat, bleaching, repeated chemical processing, relaxing, and harsh mechanical grooming. Cumulative cuticle and cortex damage producing diffuse shaft fragility.

Traction-Related Breakage

Styling tension causing shaft fracture at points of maximal stress. Distribution correlates with hairstyle. Must be distinguished from traction alopecia with follicular involvement.

Trichotillomania

Mechanically self-induced loss through pulling, twisting, or breaking. Trichoscopy reveals coiled hairs, varied lengths, and absence of true AA signs.

Clinical Pearl: Breakage often affects cosmetically stressed zones more than the entire scalp. Pattern recognition across temples, frontal hairline, crown, nape, and chemically processed areas is highly informative in directing the diagnosis.

Management Principles

Management is based on removing the damaging factor, correcting grooming habits, treating scalp inflammation where present, and setting expectations for regrowth of length rather than immediate visible density. In trichotillomania or compulsive manipulation, a supportive, non-judgmental approach and appropriate psychological referral are essential. Recovery of shaft length after eliminating the causative factor is typically gradual and requires sustained patient engagement.

MODULE 13

Principles of Cicatricial Alopecia

Cicatricial alopecias are a group of disorders in which inflammatory destruction of the follicular unit leads to permanent hair loss. This is one of the most important boundaries in hair medicine. Delay in recognition can convert a treatable inflammatory disease into irreversible cosmetic loss. For this reason, every doctor completing advanced trichology training should be able to identify the signs that distinguish active scarring disease from non-scarring alopecia.

> The central clinical imperative in cicatricial alopecia is that disease must be recognised and treated before irreversible follicular destruction occurs. Unlike diffuse shedding, cicatricial disease does not resolve with reassurance — it progresses.

13.1 — Classification of Cicatricial Alopecia

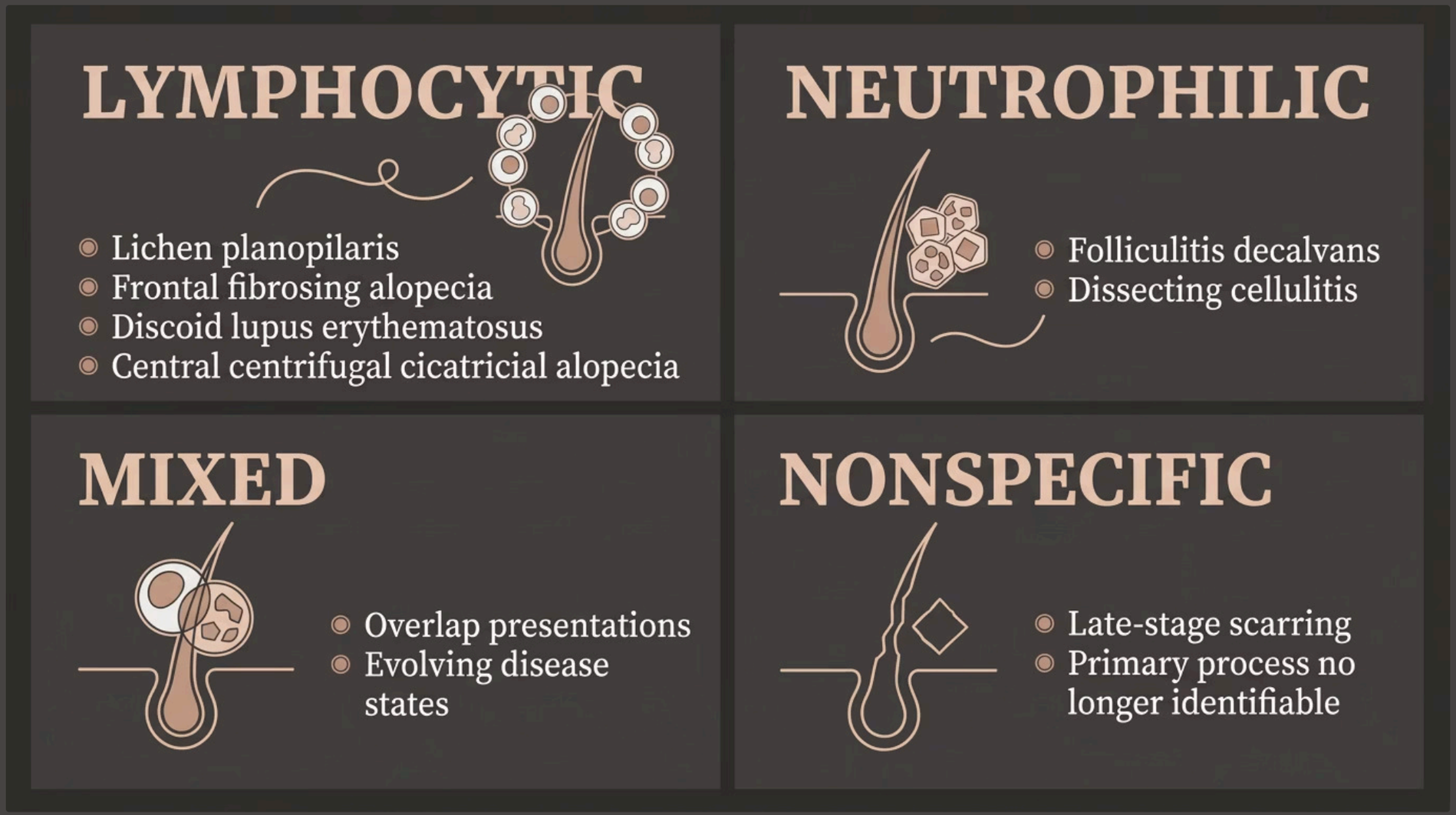

This pathological classification is clinically useful because symptoms, trichoscopy patterns, biopsy planning, and treatment strategy differ meaningfully across categories. The clinician who approaches cicatricial alopecia without this framework risks misidentifying the disease subtype and employing a treatment strategy that is inappropriate for the inflammatory mechanism driving destruction.

13.2 — Clinical Clues and Red Flags

Cardinal Signs of Cicatricial Disease

- Loss of follicular openings (ostia) on trichoscopy or naked-eye inspection
- Perifollicular scale or erythema
- Scalp pain, burning, or tenderness
- Pustules, crusting, or tufting
- Shiny, atrophic, or depressed skin surface
- Rapidly expanding patches with inflammatory symptoms
- Eyebrow loss in appropriate patterns (e.g., FFA)

Why These Signs Matter

Pain, burning, erythema, scale, pustules, and loss of follicular ostia should never be dismissed as simple dandruff or stress-related hair loss. These are markers of active inflammatory destruction, and each additional cycle of inflammation renders more follicles permanently incapable of producing terminal hair.

The scalp examination must therefore be systematic: inspect each scalp zone, assess follicular ostia, palpate for tenderness, and review trichoscopy findings before concluding that any alopecia is non-scarring.

Biopsy Urgency

In scarring alopecia, biopsy is not a last resort after months of therapeutic trial. It is often part of early disease definition and should be considered before the inflammatory architecture is lost. Choosing the correct biopsy site — an active edge rather than a scarred centre — is essential to obtaining diagnostic tissue.

13.3 — Biopsy Logic in Cicatricial Alopecia

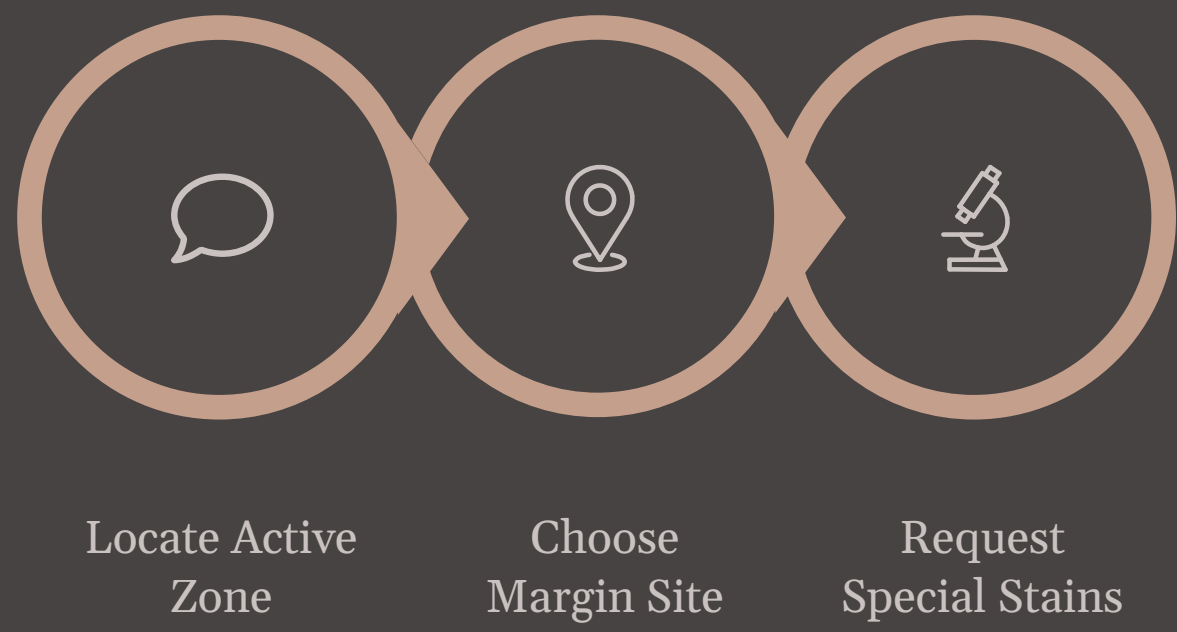

Poor site selection is the single most common reason for nondiagnostic pathology in cicatricial alopecia. A biopsy from the centre of an established scar yields only fibrosis; it cannot identify the primary inflammatory cell type, the pattern of follicular destruction, or the degree of residual activity. Correlation between clinical findings, trichoscopy, and pathology is obligatory — and the pathologist should receive a clinical summary including the working differential.

13.4 — Management Principles

1

Arrest Activity First

The first goal in cicatricial alopecia is to halt the inflammatory process, not to restore density. Cosmetic or surgical planning must be deferred until disease control is achieved.

2

Establish Stability

Stability requires sustained quiescence confirmed by symptom resolution, serial trichoscopy, and clinical photography over an adequate time period before any restorative discussion is initiated.

3

Counsel Expectations

Patients often focus on coverage while the urgent clinical need is preservation. Explicit counseling about the irreversibility of burned-out scarring is a core clinical responsibility.

MODULE 14

Lymphocytic Cicatricial Alopecias

This module focuses on the major lymphocytic scarring disorders encountered in advanced hair practice. These conditions vary in distribution and speed of progression, but share the need for early recognition, active monitoring, and treatment aimed at suppressing follicular inflammation before irreversible loss progresses. Collectively, they represent the most frequently encountered cicatricial disorders in clinical hair medicine.

14.1 — Lichen Planopilaris

Clinical Presentation

Lichen planopilaris commonly presents with perifollicular erythema, scale, symptoms of burning or tenderness, and patches of permanent loss. The scalp symptoms are often the most diagnostically useful feature, as itch, burning, and tenderness in association with hair loss should immediately raise suspicion for an inflammatory cicatricial process. Lesions may be multifocal, which can mislead clinicians who examine only a single area.

Trichoscopy in LPP may show perifollicular scaling, tubular casts, perifollicular erythema, and absence of follicular openings in established scarred zones. The tubular cast — a white peripilar keratin sleeve that sheathes the hair proximal to the scalp surface — is a particularly useful and distinctive sign of active inflammatory activity.

Key Trichoscopy Features

- Perifollicular erythema at active margins
- White peripilar tubular casts (keratin sheaths)
- Absent follicular openings in established lesions
- Interfollicular scale may be present
- Absence of yellow/black dots (helps distinguish from AA)

Clinical Urgency

Clinical urgency lies in identifying active disease before permanent spread. Early treatment can meaningfully reduce the extent of final alopecia; delayed treatment cannot recover what has been destroyed.

14.2 — Frontal Fibrosing Alopecia

Frontal fibrosing alopecia is typically characterised by progressive frontotemporal recession, eyebrow involvement, and perifollicular change at the hairline. Its presentation may initially be misread as patterned loss or traction alopecia, but the presence of perifollicular inflammation, eyebrow change, facial papules in some patients, and the quality of the recession margin should prompt clinical suspicion.

Recession Pattern

Frontotemporal hairline recession with a distinctive "lonely hair" sign — isolated hairs persisting within the recession zone with surrounding perifollicular erythema and scale

Eyebrow Involvement

Lateral eyebrow thinning is present in a substantial proportion of FFA patients and may precede scalp recession. Always examine the brows in any woman presenting with frontal hair loss.

Eyelash & Body Hair

Progressive eyelash loss, axillary hair loss, and facial hair involvement (including facial papules from vellus hair follicle inflammation) are recognised features.

Differential Diagnosis

Distinguish from female pattern hair loss, traction alopecia, and LPP affecting the frontal scalp. Trichoscopy and biopsy correlation are required when the distinction is not clinically clear.

14.3 — Discoid Lupus Erythematosus & CCCA

14.3 — Discoid Lupus Erythematosus

Discoid lupus erythematosus may present on the scalp with erythematous plaques, adherent scale, follicular plugging, dyspigmentation (both hypopigmentation and hyperpigmentation), atrophy, and scarring. Because scalp lesions can be patchy and mimic other inflammatory diseases, biopsy correlation with direct immunofluorescence is especially important for diagnostic confirmation.

Clinicians must also consider systemic disease context when DLE is identified on the scalp, although isolated cutaneous disease without systemic involvement is common. Thorough review of systemic symptoms and serologic testing guide risk stratification.

14.4 — Central Centrifugal Cicatricial Alopecia

CCCA classically begins near the vertex and expands centrifugally, often with tenderness, itch, or burning. It is more prevalent in women of African descent, and cultural and grooming practices must be addressed sensitively and within a clinical framework that neither ignores relevant habits nor reduces the diagnosis to a grooming-caused condition.

CCCA requires thoughtful differentiation from advanced female pattern hair loss and chronic grooming-related injury. Biopsy is often necessary to confirm the diagnosis, particularly when the clinical presentation is ambiguous.

14.5 — Practical Management of Lymphocytic Cicatricial Alopecias

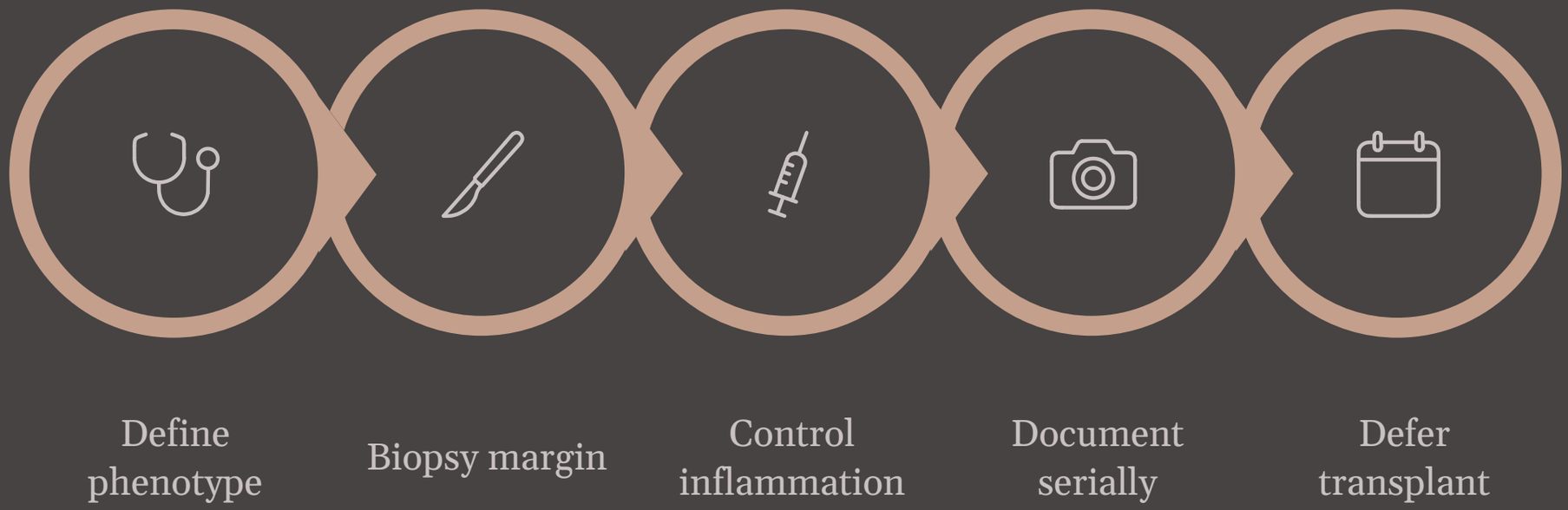

Serial documentation is not optional in cicatricial alopecia management — it is the primary tool for determining whether treatment is working, whether disease is progressing despite treatment, and whether stability has been achieved to a degree that justifies any restorative conversation. Photography and trichoscopy at defined intervals provide objective benchmarks that clinical memory alone cannot supply.

LMS Mapping Note: Each lymphocytic disorder should later become a case-based lesson with trichoscopy image interpretation, biopsy site selection, and stability assessment before any restorative discussion is introduced.

MODULE 15

Neutrophilic and Mixed Cicatricial Alopecias

Neutrophilic cicatricial disorders often declare themselves through pustules, crusting, pain, discharge, tufting, and aggressive follicular destruction. These cases can be clinically distressing and diagnostically challenging, and often require a high index of clinical suspicion in patients who have long been managed as simple or recurrent folliculitis without adequate diagnostic evaluation or disease-specific treatment.

15.1 — Folliculitis Decalvans

Clinical Presentation

Folliculitis decalvans presents with recurrent pustules, perifollicular crusting, tufted hairs, and spreading scarring patches. Tufting — the appearance of multiple hair shafts emerging from a single enlarged follicular opening surrounded by fibrosis — is a classic and highly characteristic sign of this condition. The clinician must assess microbial contribution, inflammatory activity, symptom burden, and secondary damage from manipulation.

The role of *Staphylococcus aureus* in perpetuating inflammation in folliculitis decalvans is well documented, though the condition is not simply an infectious disease. Treatment directed solely at bacteria without addressing the inflammatory component is typically insufficient.

Management Approach

- Bacterial culture and sensitivity to guide antimicrobial selection
- Combined anti-inflammatory and antimicrobial strategy
- Long-duration courses often required to prevent recurrence
- Topical antiseptic measures as adjuncts
- Monitor for secondary damage from excoriation or crust manipulation
- Serial photography and trichoscopy to track activity
- Realistic counseling about chronic relapsing course

15.2 — Dissecting Cellulitis & Management Principles

15.2 — Dissecting Cellulitis

Dissecting cellulitis of the scalp is a severe inflammatory disease characterised by fluctuant nodules, abscess-like interconnected lesions, sinus tract formation, and progressive scarring. It occurs predominantly in young men of African descent and may coexist with broader follicular occlusion syndromes including hidradenitis suppurativa and acne conglobata — a combination known as the follicular occlusion tetrad when pilonidal cyst is also present.

Early recognition matters because progressive destruction and psychosocial burden can be profound. Imaging with ultrasound can help define the extent of subcutaneous involvement and guide therapeutic decisions.

15.3 — Management Principles

Treatment requires control of active inflammation and secondary infection risk, reduction of drainage and pain, and realistic longitudinal planning. In extensive or refractory disease, management may require multidisciplinary input including dermatology, general medicine, and where appropriate, psychology.

Doctors must learn that apparent response in surface symptoms does not always equal disease control. Active subcutaneous disease may persist below a clinically quieter surface. Serial examination, photography, and symptom review remain essential throughout the treatment course.

Red Flags: Tufting, pustules, crusts, draining nodules, and pain with expanding permanent loss are signs of destructive active disease requiring more than cosmetic assessment or simple antibiotic courses.

MODULE 16

Inflammatory and Infectious Scalp Disorders

Common scalp disorders are often dismissed as secondary concerns, yet they can worsen shedding, mimic alopecia, aggravate symptoms, disrupt treatment adherence, and reduce the reliability of examination. A strong physician-level trichology program must therefore teach scalp disease as integral to hair diagnosis rather than as a separate cosmetic concern. The scalp is not merely the substrate on which hair loss occurs — it is a dynamic skin organ whose condition directly influences diagnostic accuracy and treatment outcome.

16.1 — Seborrhoeic Dermatitis & Psoriasis

16.1 — Seborrhoeic Dermatitis

Seborrhoeic dermatitis typically presents with scale, erythema, pruritus, and fluctuating severity influenced by stress, seasonal change, and immune status. It may coexist with patterned loss or TE and can increase patient distress out of proportion to objective severity. The inflammatory component may contribute to shedding in susceptible patients, and effective control can reduce both scalp symptoms and hair loss burden.

Clinical management includes barrier support, anti-inflammatory control, and antifungal logic where appropriate. The role of *Malassezia* species in driving seborrhoeic dermatitis supports the use of antifungal agents as part of long-term maintenance, not only as acute treatment.

16.2 — Scalp Psoriasis

Scalp psoriasis may cause marked scale, erythema, discomfort, and temporary shedding while usually remaining non-scarring unless significant secondary damage occurs through mechanical trauma or prolonged severe inflammation. Doctors must distinguish psoriasis from seborrhoeic dermatitis, contact dermatitis, and overlap patterns — a clinically common challenge given the similarity of appearance.

The presence of well-demarcated, thick, silvery scale, associated nail changes, joint symptoms, or family history of psoriasis supports the diagnosis. Dermoscopy can assist in distinguishing psoriatic from seborrhoeic patterns when the clinical picture is ambiguous.

16.3–16.4 — Contact Dermatitis and Tinea Capitis

16.3 — Contact Dermatitis and Irritant Disease

Hair dyes, topical therapeutic agents, medicated preparations, adhesives, and cosmetic products can trigger irritant or allergic contact dermatitis of the scalp. The patient who reports worsening itch, redness, burning, or shedding after starting a new topical treatment requires careful review of the scalp barrier and all applied products. The temporal relationship between product introduction and symptom onset is often the most informative diagnostic clue.

Patch testing should be considered when allergic contact dermatitis is suspected. Para-phenylenediamine (PPD) in hair dyes is among the most common sensitizers encountered in this context. Management requires identification and removal of the offending agent as well as barrier restoration.

16.4 — Tinea Capitis and Scalp Infection

Clinical Features

Broken hairs, black dot pattern, scale, erythematous plaques, occipital or cervical lymphadenopathy, and focal patchy loss

Adult Presentation

Less common than in paediatric settings but should not be dismissed; immunosuppressed, elderly, and institutionalised adults are at higher risk

Inflammatory End-Spectrum

Kerion formation — a boggy, inflammatory, exudative mass — can scar if diagnosis is delayed. High clinical suspicion and mycology are essential.

Diagnosis

Wood's lamp, scalp scraping, hair plucking for mycology, and culture. Systemic antifungal therapy required — topical agents alone are insufficient for dermatophyte scalp infection.

16.5 — Building a Scalp Barrier Treatment Plan

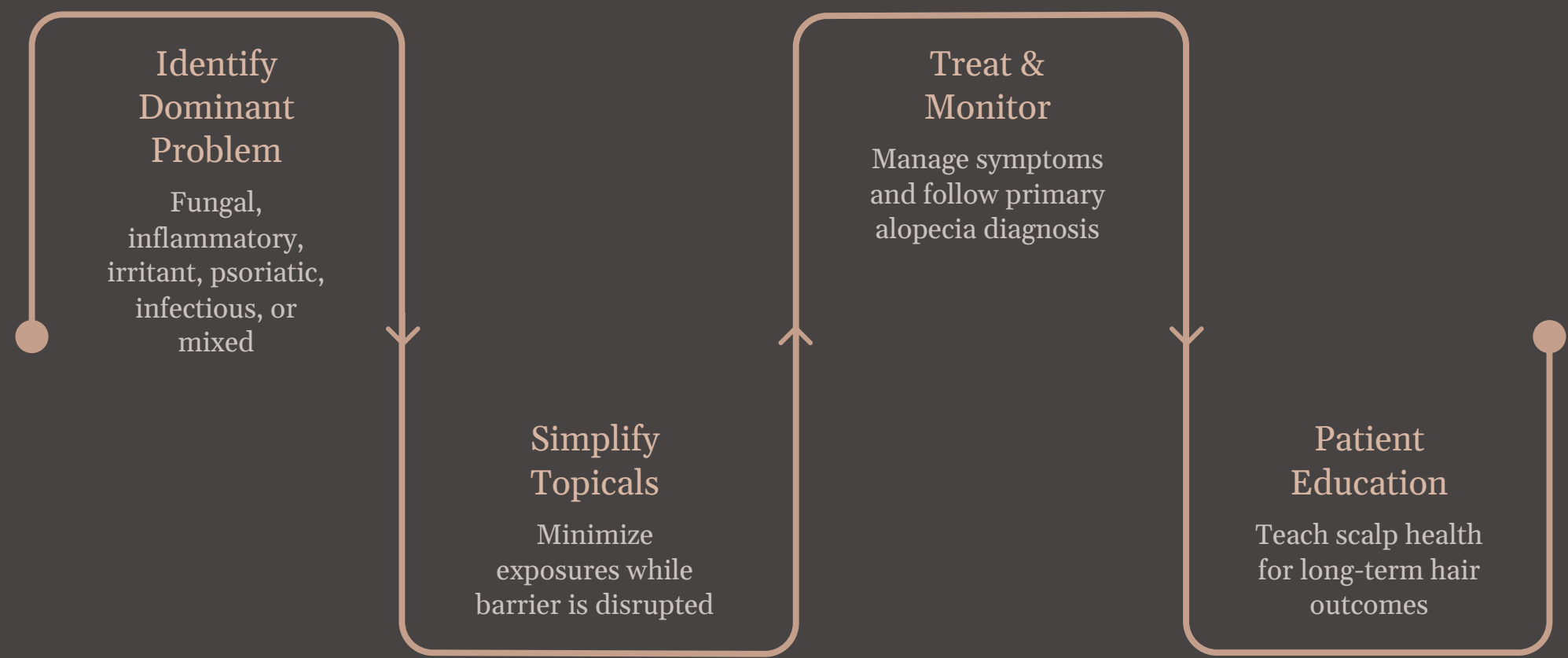

Treating the scalp as a skin organ — subject to the same principles of inflammation, barrier function, and disease-specific management that guide dermatologic practice elsewhere — elevates the standard of hair medicine significantly. The clinician who resolves scalp inflammation often finds that the underlying alopecia becomes more accurately assessable and more responsive to targeted treatment.

Define the Dominant Problem

Differentiate fungal, inflammatory, irritant, psoriatic, infectious, and mixed etiologies before initiating treatment. Overlapping pathology is common and must be addressed in sequence or simultaneously.

Simplify Topical Exposure

When the barrier is disrupted, reduce the total number of applied products. Multiple topical agents on a compromised barrier increase the risk of sensitization and irritation perpetuating the cycle.

Monitor the Alopecia Diagnosis

Treat scalp symptoms actively but reassess the primary hair loss diagnosis as inflammation settles. Some alopecia diagnoses clarify considerably once confounding scalp disease is controlled.

Patient Education

Scalp comfort, inflammation control, and treatment adherence are part of long-term hair outcome. Patients who understand this connection are more likely to maintain consistent therapeutic engagement.

End-of-Volume Integration

By the end of Volume 3, the learner should be able to distinguish transient shedding from structural follicular disease, recognise immune-mediated and cicatricial alopecias early, use trichoscopy and biopsy logic more intelligently, and integrate scalp disease into the overall management plan. This represents a major transition point in the academy: the learner moves from understanding common patterned loss into the broader discipline of clinical hair pathology.

Module 10

Differentiate TE types, map trigger timelines, manage chronic and overlapping shedding presentations

Module 11

Recognise AA phenotypes, interpret trichoscopy, build treatment frameworks for mild through extensive disease

Module 12

Separate breakage from shedding, classify shaft disorders, manage grooming-related and compulsive loss

Modules 13–15

Classify and recognise cicatricial disease early, apply biopsy logic, prioritise anti-inflammatory control before restoration

Module 16

Diagnose and treat inflammatory and infectious scalp disease as integral to the alopecia workup

> **Assessment Directions:** Volume 3 assessment should include image-based trichoscopy interpretation, biopsy-site selection exercises, scarring vs. non-scarring differentials, and case-based treatment sequencing exercises.

Volume 3 — Multiple Choice Assessment

The following questions are designed to assess physician-level comprehension of the clinical concepts presented in Modules 10–16. Select the single best answer for each question. Questions are structured to test diagnostic reasoning, trichoscopy interpretation, classification, and management prioritisation rather than simple recall.

Question 1

A 34-year-old woman presents with a four-month history of increased daily hair shedding following a severe respiratory illness. She denies any scalp symptoms, focal bald patches, or eyebrow change. Trichoscopy shows globally reduced density with a normal distribution of hair calibre and no yellow dots or black dots. The pull test is positive diffusely. Which of the following is the most appropriate next step?

A
Initiate minoxidil therapy immediately

B
Perform a scalp biopsy to exclude scarring alopecia

C
Establish the trigger timeline, perform targeted laboratory testing, and provide counselling on expected recovery

D
Diagnose chronic telogen effluvium and refer for psychological support

Question 2

A physician examining a patient with diffuse hair loss finds numerous yellow dots and scattered black dots on trichoscopy. The patient reports rapid onset shedding over two months without an identifiable trigger. Which diagnosis should be prioritised in the differential?

A
Acute telogen effluvium secondary to nutritional deficiency

B
Alopecia areata incognita

C
Diffuse androgenetic alopecia

D
Frontal fibrosing alopecia

Question 3

Which of the following trichoscopic findings is most specific for active alopecia areata?

A
Peripilar tubular casts

B
Perifollicular erythema at the hairline

C
Exclamation-mark hairs

D
Trichoptilosis and varied shaft length

Question 4

A 28-year-old woman complains that her hair is thinning despite no notable increase in daily hair fall. Trichoscopy reveals globally preserved follicular density but numerous broken hairs of varied length, with particularly dense short hairs along the chemically processed mid-lengths and ends. Which of the following is the most appropriate interpretation?

A
Chronic telogen effluvium with secondary follicular miniaturisation

B
Shaft breakage disorder secondary to acquired weathering and chemical processing

C
Alopecia areata incognita presenting with preserved follicular density

D
Early lichen planopilaris with perifollicular involvement

Question 5

When performing a biopsy in a patient with suspected cicatricial alopecia, which of the following site selections will most reliably yield a diagnostic specimen?

A
The centre of the most extensively scarred and hairless zone

B
An area of normal-appearing scalp at the periphery of the lesion

C
The active inflammatory margin where trichoscopy shows perifollicular change

D
Any accessible site, as histopathology is uniformly informative throughout the scalp

Question 6

A patient with frontal fibrosing alopecia asks when she can proceed with hair transplantation. She reports that her hairline has been stable for five months. Which of the following is the most appropriate response?

A
Hair transplantation can be performed immediately given five months of apparent stability

B
Restorative procedures should be deferred until durable disease quiescence is confirmed by serial clinical, trichoscopic, and symptomatic assessment over an adequate period

C
Transplantation should never be considered in any cicatricial alopecia

D
Anti-inflammatory therapy should be discontinued before any surgical planning is undertaken

Question 7

Which of the following is the most characteristic trichoscopic sign of active lichen planopilaris?

A
Yellow dots and black dots in the patch

B
Peripilar white tubular casts (keratin sheaths) at active follicular margins

C
Exclamation-mark hairs at the patch border

D
Moth-eaten pattern with preserved shaft thickness

Question 8

Folliculitis decalvans is best understood as:

A
A purely infectious disease caused by Staphylococcus aureus that resolves with appropriate antibiotics alone

B
A neutrophilic cicatricial alopecia in which microbial and inflammatory components both contribute, requiring combined and often long-duration treatment

C
A lymphocytic cicatricial disorder related to lichen planopilaris

D
A non-scarring inflammatory folliculitis that resolves without permanent sequelae

Question 9

A 22-year-old man presents with fluctuant scalp nodules, sinus tract formation, and diffuse scarring over the vertex. He also has a history of hidradenitis suppurativa. Which of the following diagnoses is most consistent with this presentation?

A
Folliculitis decalvans

B
Dissecting cellulitis of the scalp

C
Discoid lupus erythematosus

D
Kerion secondary to tinea capitis

Question 10

Which of the following is the most appropriate initial diagnostic step when tinea capitis is suspected in a patient with focal patchy alopecia, broken hairs, and scalp scale?

A
Initiate empirical topical antifungal shampoo and review in eight weeks

B
Perform scalp scraping and hair plucking for mycology and culture, and initiate systemic antifungal therapy

C
Perform a scalp biopsy immediately to exclude cicatricial alopecia

D
Diagnose seborrhoeic dermatitis and prescribe a zinc pyrithione shampoo

Question 11

A patient with diffuse hair loss and a history of severe crash dieting six months ago is labelled as having chronic telogen effluvium. Which of the following findings on examination would most strongly indicate that this label should be reconsidered?

A
Positive pull test with club hairs

B
Global reduction in density without focal patches

C
Perifollicular erythema, loss of follicular ostia, and scalp tenderness

D
Low serum ferritin on laboratory testing

Question 12

In central centrifugal cicatricial alopecia (CCCA), which of the following distinguishes the condition from advanced female pattern hair loss at the vertex?

A
CCCA exclusively affects women over the age of 50

B
CCCA is associated with perifollicular inflammation, symptoms of tenderness or burning, and loss of follicular openings in the central zone

C
CCCA never extends beyond the vertex and is always asymptomatic

D
Female pattern hair loss invariably produces perifollicular scale visible on trichoscopy

Question 13

A patient with seborrhoeic dermatitis and concurrent androgenetic alopecia reports worsening itch and burning after commencing a new compounded topical treatment for hair loss. The most appropriate next step is:

A
Increase the frequency of the topical treatment to overcome barrier resistance

B
Review all applied scalp products, consider contact or irritant dermatitis as the cause, and simplify topical exposure while assessing the barrier

C
Diagnose sebopsoriasis and initiate systemic treatment immediately

D
Stop all topical treatments and reassess in six months

Question 14

Which of the following best characterises the ophiasis pattern in alopecia areata?

A
Diffuse involvement of the entire scalp without discrete patches

B
Band-like loss along the occipital and temporal scalp margins, associated with a worse prognosis than patchy disease

C
Complete loss of eyebrows and eyelashes with preserved scalp hair

D
Vertex-predominant scarring loss with centrifugal expansion

Question 15

In the management of scalp psoriasis overlapping with non-scarring alopecia, which of the following is the most important clinical principle?

A
Treat psoriasis and ignore the hair loss diagnosis until the skin is clear

B
Avoid all topical agents to prevent contact sensitisation

C
Treat scalp inflammation actively while monitoring whether the underlying hair loss diagnosis clarifies as the inflammatory burden resolves

D
Diagnose psoriatic scarring alopecia and plan surgical restoration

Volume 3 Assessment — Answer Key & Explanations

The following provides the correct answer and a concise clinical rationale for each question. These explanations reinforce the diagnostic reasoning and management principles taught across Modules 10–16.

Q1 — Answer: C

Establish the trigger timeline, perform targeted laboratory testing, and provide counseling on expected recovery. This presentation is consistent with acute TE following febrile illness. The absence of trichoscopic red flags, focal patches, or inflammatory signs supports this. The most productive next step is to map the trigger timeline, exclude metabolic or endocrine contributors with focused testing (CBC, ferritin, TSH), and counsel on expected recovery latency. Immediate minoxidil (A) is premature. Biopsy (B) is not indicated without signs of cicatricial disease. Diagnosis of chronic TE (D) is inaccurate given the history and short duration.

Q2 — Answer: B

Alopecia areata incognita. Yellow dots and black dots are cardinal trichoscopic signs of alopecia areata, not telogen effluvium. In diffuse presentations without discrete patches, AA incognita must be considered before labelling the case as TE. Diffuse AGA (C) does not produce yellow or black dots. FFA (D) presents with frontotemporal recession and perifollicular inflammation, not diffuse shedding with these trichoscopy findings.

Q3 — Answer: C

Exclamation-mark hairs. Exclamation-mark hairs — tapered proximal shafts with a normal distal diameter — are highly specific for active AA and reflect proximal dystrophic shaft formation under inflammatory attack on the hair bulb. Peripilar tubular casts (A) are the hallmark of LPP. Perifollicular erythema at the hairline (B) is characteristic of FFA. Trichoptilosis and varied shaft length (D) indicate shaft breakage, not AA.

Q4 — Answer: B

Shaft breakage disorder secondary to acquired weathering and chemical processing. Preserved follicular density with numerous broken hairs of varied length, particularly in chemically processed areas, is the pattern of shaft breakage rather than follicular shedding or alopecia. The patient's complaint of thinning without increased shedding is a key distinguishing feature. No trichoscopic signs of AA incognita (C) or cicatricial disease (D) are described.

Q5 — Answer: C

The active inflammatory margin where trichoscopy shows perifollicular change. Biopsy from the centre of established scarring (A) yields only fibrosis and cannot identify the primary inflammatory cell type or disease activity. Normal-appearing scalp (B) is also non-diagnostic. The active margin — identified by trichoscopy as the zone with perifollicular inflammation, scale, or erythema — provides the most diagnostically informative tissue. Site selection is a core skill in cicatricial alopecia management.

Q6 — Answer: B

Restorative procedures should be deferred until durable disease quiescence is confirmed by serial assessment over an adequate period. Five months of apparent stability is insufficient to confirm durable quiescence in FFA. Transplantation into active or incompletely controlled scarring disease risks further follicular destruction and poor graft survival. Stability must be confirmed by symptom resolution, trichoscopic quiescence, and clinical photography over a sustained period. Transplantation is not permanently contraindicated (C), but timing is critical.

Q7 — Answer: B

Peripilar white tubular casts (keratin sheaths) at active follicular margins. Tubular casts — white peripilar keratin sleeves at the follicular margin — are a distinguishing trichoscopic feature of active LPP. Yellow dots and black dots (A) are signs of alopecia areata. Exclamation-mark hairs (C) indicate AA activity. The moth-eaten pattern (D) is associated with secondary syphilis.

Q8 — Answer: B

A neutrophilic cicatricial alopecia in which microbial and inflammatory components both contribute, requiring combined and often long-duration treatment. Although Staphylococcus aureus plays a role in FD, treating it as a purely infectious condition (A) leads to inadequate management and recurrence. FD is classified as a neutrophilic cicatricial disorder. It is not related to LPP (C) and does produce permanent scarring (D). Long-duration combined anti-inflammatory and antimicrobial therapy is typically required.

Q9 — Answer: B

Dissecting cellulitis of the scalp. The combination of fluctuant nodules, sinus tracts, scarring, and coexisting hidradenitis suppurativa is characteristic of dissecting cellulitis — a neutrophilic/mixed cicatricial disorder associated with the follicular occlusion spectrum. Folliculitis decalvans (A) typically presents with tufting and surface pustules without sinus tracts. DLE (C) presents with erythematous plaques and scale. Kerion (D) is an acutely inflamed fungal mass, not a sinus-tract-forming disorder.

Q10 — Answer: B

Perform scalp scraping and hair plucking for mycology and culture, and initiate systemic antifungal therapy. Topical antifungals alone (A) are insufficient for dermatophyte scalp infection, which requires systemic treatment. Immediate biopsy (C) is not the first step when fungal disease is the leading differential. A definitive mycologic diagnosis should be sought, and systemic therapy initiated without waiting for culture results if the clinical suspicion is high, adjusting upon confirmation.

Q11 — Answer: C

Perifollicular erythema, loss of follicular ostia, and scalp tenderness. These are cardinal signs of active cicatricial alopecia. A positive pull test with club hairs (A) and global density reduction (B) are consistent with TE. Low ferritin (D) supports a TE or FPHL contributor but does not indicate a need to change the label. Perifollicular inflammation and loss of follicular openings should never be attributed to TE — they mandate reclassification and biopsy consideration.

Q12 — Answer: B

CCCA is associated with perifollicular inflammation, symptoms of tenderness or burning, and loss of follicular openings in the central zone. These inflammatory and scarring features distinguish CCCA from FPHL, which does not involve follicular destruction. CCCA is not restricted to women over 50 (A), nor is it always asymptomatic or restricted to the vertex (C). FPHL does not produce perifollicular scale characteristic of cicatricial disease (D).

Q13 — Answer: B

Review all applied scalp products, consider contact or irritant dermatitis as the cause, and simplify topical exposure while assessing the barrier. New-onset itch and burning after initiating a topical agent in the context of known seborrhoeic dermatitis should prompt consideration of contact or irritant dermatitis. Increasing treatment frequency (A) is inappropriate and likely to worsen barrier disruption. Stopping all treatment without evaluation (D) is reactive rather than diagnostic. Immediate systemic therapy (C) is premature.

Q14 — Answer: B

Band-like loss along the occipital and temporal scalp margins, associated with a worse prognosis than patchy disease. Ophiasis is defined by its marginal distribution along the lower temporal and occipital scalp. It carries a worse prognosis than isolated patchy AA due to its extent and resistance to standard therapies. The sisaipho pattern (inverse ophiasis) shows retention of marginal hair. Diffuse involvement without patches (A) describes AA incognita. Eyebrow/eyelash loss with scalp retention (C) is a distinct phenotype. Vertex scarring (D) describes CCCA.

Q15 — Answer: C

Treat scalp inflammation actively while monitoring whether the underlying hair loss diagnosis clarifies as the inflammatory burden resolves. Scalp disease is integral to the hair diagnosis, not separate from it. Treating psoriasis while continuing to monitor the alopecia picture as inflammation settles is the most clinically sound approach. Ignoring the hair loss (A) risks missing an evolving diagnosis. Avoiding all topicals (B) is impractical and likely to worsen psoriasis. Diagnosing psoriatic scarring alopecia (D) is premature without evidence of cicatricial change.

Assessment Note: A passing standard of 70% (11/15 correct) is recommended for progression. Questions answered incorrectly should be reviewed in the context of the relevant module section before the learner proceeds to Volume 4 or any clinical practicum assessment.